

# A Chairside Technique to Preserve the Anatomy of the Pre-Existing Crown in Immediate Implant Provisionalization: A Case Report

Una Técnica de Sillón para Preservar la Anatomía de la Corona Preexistente en Provisionalización Inmediata de Implantes: Presentación de un Caso

Jorge Jofre

**JOFRE, J.** A chairside technique to preserve the anatomy of the pre-existing crown in immediate implant provisionalization: A case report. *Int. J. Odontostomat.*, 4(3):291-294, 2010.

**ABSTRACT:** The aim of this article is to describe a chairside method for immediate implant provisionalization, which preserves the original natural emergence profile and anatomy of the teeth.

**KEY WORDS:** dental esthetics, immediate dental implant, immediate provisionalization, technical procedure, temporary, tooth extraction, emergence profile.

## INTRODUCTION

Immediate implant placement is a well-accepted protocol and has become a viable treatment option (De Rouck *et al.*, 2008). This procedure can be associated with immediate provisionalization, reducing treatment time and preserving the periodontal architecture that contributes to final esthetics (Block *et al.*, 2009).

It has been reported that procedures for immediate provisionalization require laboratory work (Block *et al.*; Chen & Pow, 2008), which is time and cost consuming.

Margeas (2006) and Chen & Pow, reported the use of the patient's natural teeth as a provisional piece in order to preserve the tooth emergence profile. However, most tooth extractions in which provisionalization is indicated are related to teeth treated with metal ceramic crowns or extreme crown reconstructions. These crowns are difficult to handle when adjusting the cervical margin to the abutment.

Herein, a method for immediate implant provisionalization is described and illustrated in detail. This method preserves the emergence profile of the peri-implant tissue, replicating the pre-existing anatomical crown with acrylic.

## CASE REPORT

A 65-year-old female visited the University Clinical Center complaining of discomfort and mobility in tooth 4.3, which hindered the use of her lower RPD (Fig. 1a). The patient's clinical examination showed a healthy oral state and treated periodontitis. Piece 4.3 had degree 3 mobility and a high level of bone loss (Fig. 1b). This tooth had to be extracted in order to retain the patient's oral function, and piece 4.3 was replaced with an immediate implant provisionalization having the same shape as the pre-existing anatomical crown and fit to the RPD.

The provisionalization method considers the following steps:

- 1.- Develop a silicone index to guide the provisional to the final position.
- 2.- Under local anesthesia (lidocaine hydrochloride 2% with epinephrine 1:100.000), extract the tooth (in our case, piece 4.3) with a free flap technique, avoiding damage to the gingival tissue and alveolar walls.
- 3.- Place an immediate implant, connecting a provisional abutment. Primary stability must be considered to be adequate (torque value  $\geq 35$ Ncm).
- 4.- Make a block of addition silicone (putty consistency) and submerge the crown, taking care to completely

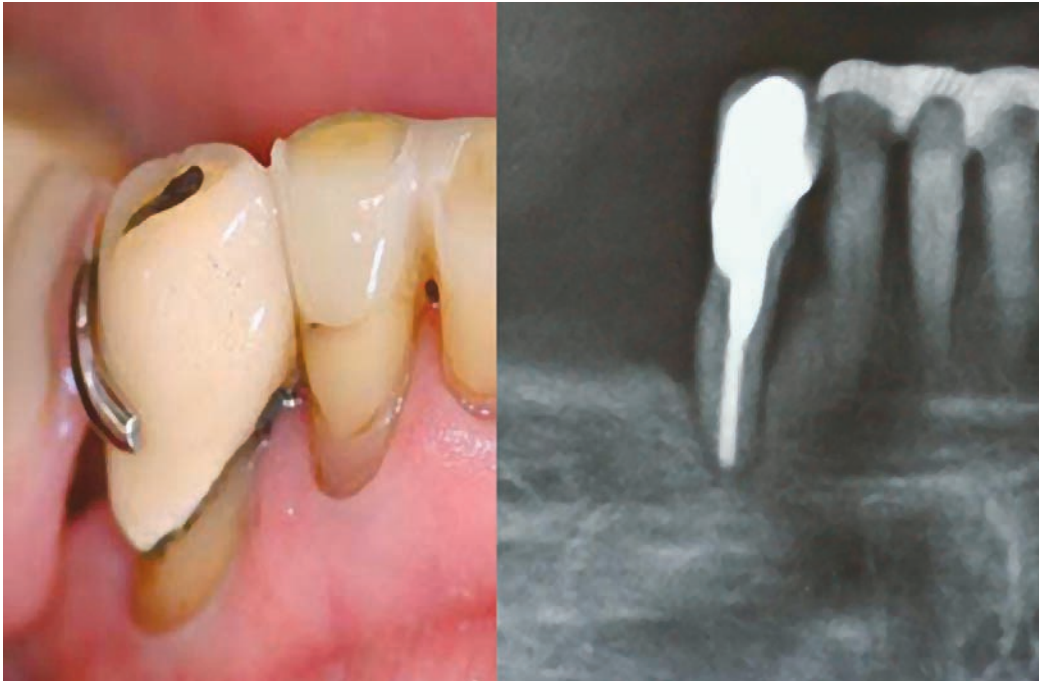

Fig. 1. a) Pre-existing crown supporting a removable partial denture (RPD).  
Fig. 1. b) Initial X-ray.

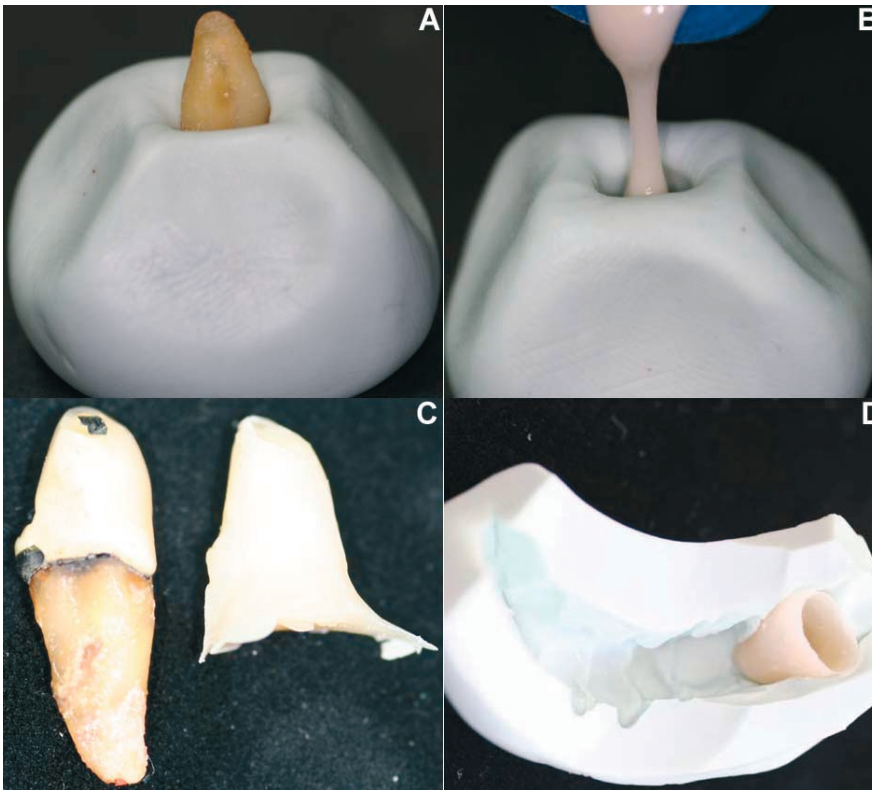


Fig. 2. A technique to elaborate a provisional restoration. A) Extracted tooth inserted in putty silicone (Speedex; Coltène / Whaledent, Alstätte, Switzerland); B) After removing the crown from the silicone block, fluid acrylic (Alike; GC America, Alsip, IL) was poured into the mold; C) Extracted crown and hollowed replica.

cover the emergence profile (Figure 2a).

5.- Remove the crown from the silicone and fill the mold with acrylic fluid (Alike; GC America, Alsip, IL) (Fig. 2b).

6.- Remove the acrylic duplicate from the silicone block and hollow out (Fig. 2c, d).

7.- Use a silicone index to position the tooth.

8.- Reline the crown with acrylic on the provisional abutment and wait for the acrylic setting time, making slight vertical movements to avoid retention.

9.- Remove excess acrylic, and polish the acrylic crown outside of the mouth.

10.- Use provisional cement (TempoCem®NE, DMG, Hamburg, Germany) on the crown.

11.- Check that the provisional has no contact in centric and eccentric occlusion.

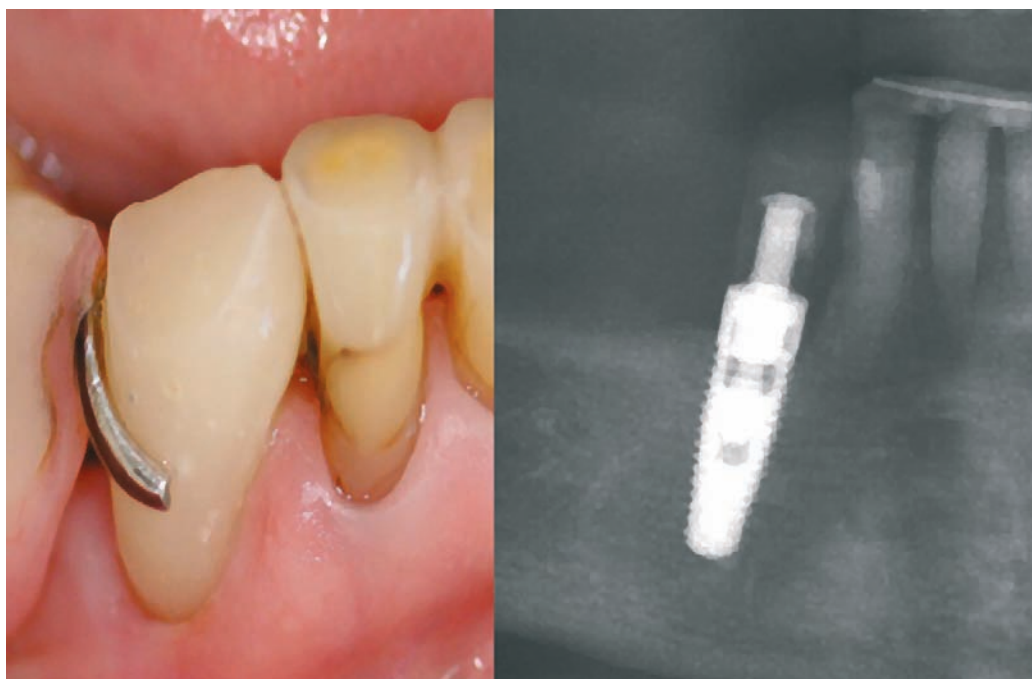


Fig. 3. Immediate implant provisionalization fitting an existing RPD after three months of clinical use. b) Radiographic control.

12.- The patient was monitored three times: at 48 hours, one week, and three months after surgery. No pain or signs of infection were found. The patient did not report

any discomfort with her prosthesis and indicated a high level of satisfaction with the immediate treatment and the aesthetic results obtained (Fig. 3a, b).

## DISCUSSION

Immediate provisionalization is considered to be an advantageous procedure for aesthetic results in immediate implant placement. Despite reports of techniques and procedures that use the patient's teeth, these cannot always be recovered. The method described offers a chairside alternative for fabricating an immediate provisional for a single implant, replicating the pre-existing anatomical crown with acrylic. Acrylic is easier to handle for this procedure, and allows the periodontal structures to be preserved.

The applications of this technique are extensive, and can be used on anterior and posterior teeth as well as fixed partial prosthetics and bridges.

## CONCLUSION

This chairside technique replicates the pre-existing natural or restored teeth, preserving the original natural emergence profile and anatomical crown.

## ACKNOWLEDGEMENTS

The author thanks Paula Quintana (DDS) and Jeanette Fuentes (DDS) for critical readings of this manuscript and Claudia Asenjo (MS) for drafting the manuscript.

---

JOFRE, J. Una técnica de sillón para preservar la anatomía de la corona preexistente en provisionalización inmediata de implantes: Presentación de un caso. *Int. J. Odontostomat.*, 4(3):291-294, 2010.

**RESUMEN:** El objetivo de este artículo es describir un método directo en el sillón de provisionalización inmediata del implante, que conserva el perfil de emergencia natural original y la anatomía de los dientes.

**PALABRAS CLAVE:** estética dental, implantes dentales inmediatos, provisionalización inmediata, procedimiento técnico, extracción de dientes, perfil de emergencia.

## REFERENCES

De Rouck, T.; Collys, K. & Cosyn, J. Single-tooth replacement in the anterior maxilla by means of immediate implantation and provisionalization: a review. *Int. J. Oral Maxillofac. Implants*, 23:897-904, 2008.

Block, M. S.; Mercante, D. E.; Lirette, D.; Mohamed, W.; Ryser, M. & Castellon, P. Prospective evaluation of immediate and delayed provisional single tooth restorations. *J. Oral Maxillofac. Surg.*, 67:89-107, 2009.

Chen, Z. F. & Pow, E. H. A technique for the fabrication of an immediate implant-supported provisional restoration using a fractured natural tooth. *J. Prosthet. Dent.*, 100:157-8, 2008.

Margeas, R. C. Predictable periimplant gingival esthetics: use of the natural tooth as a provisional following implant placement. *J. Esthet. Restor. Dent.*, 18:5-12, 2006.

Correspondence to:

Dr. Jorge Jofre

Center for Advanced Prosthodontics and Implant Dentistry (CRAI)

Universidad de Concepción

Concepción

CHILE

Phone: (56-41) 220-3770

Fax: (56-41) 220-3706

Email: [jjofre@udec.cl](mailto:jjofre@udec.cl)

Received: 05-11-2010

Accepted: 27-11-2010